

Transrectal ultrasonography and plasma progesterin profiles identifies fetoplacental compromise in mares with experimentally induced placentitis

Steffani Morris^a, Audrey A. Kelleman^a, Robert J. Stawicki^a, Peter J. Hansen^b, Peter C. Sheerin^c, Barbara R. Sheerin^a, Dale L. Paccamonti^d, Michelle M. LeBlanc^{c,*}

^a Department of Large Animal Clinical Sciences, College of Veterinary Medicine, Gainesville, FL 32611-0910, USA

^b Department of Animal Sciences, University of Florida, Gainesville, FL 32611-0910, USA

^c Rood and Riddle Equine Hospital, Lexington, KY 40580, USA

^d Department of Veterinary Clinical Sciences, School of Veterinary Medicine, Louisiana State University, Baton Rouge, LA 70803, USA

Received 2 November 2004; accepted 14 May 2006

Abstract

Transrectal ultrasonography of the caudal uterus and a progesterin profile were evaluated for accuracy in identifying mares with fetoplacental compromise in a model of placentitis. Twenty-two pregnant ponies were divided into four groups: (1) control mares ($n = 5$); (2) instrumented controls ($n = 2$); (3) instrumented inoculated mares ($n = 11$); (4) inoculated mares ($n = 4$). Mares in Groups 3 and 4 were inoculated with *Streptococcus equi* subsp. *zooepidemicus*. Maternal plasma progesterins, vulvar discharge, mammary gland development, combined thickness of the uterus and placenta (CTUP) and placental separation were evaluated weekly before instrumentation, inoculation or Day 320 (Groups 1 and 2) and, thereafter, either daily (first three measurements) or several times weekly (last two measurements). Plasma progesterin profiles were plotted to identify pattern characteristics. An abbreviated profile was created, consisting of four progesterin samples collected at 48-h intervals, with Sample 1 collected the day before inoculation or on Day 285 in controls. Profiles were considered abnormal if Samples 2, 3, or 4 increased or decreased by more than 50% of Sample 1. A CTUP > 1.0 cm or placental separation were considered abnormal. Placentitis was confirmed by histology of fetal membranes. Control mares had normal progesterin profiles, transrectal ultrasonographic and clinical examinations. Control foals were born after Day 329; six were viable and one died after dystocia. All inoculated mares developed placentitis and foaled before Day 314. Thirteen of 15 foals were not viable. All inoculated mares had abnormal progesterin profiles and 13 of the 15 were identified by the abbreviated progesterin profile. Transrectal CTUP was affected by gestational age and increased after inoculation ($P < 0.05$). Nine of 15 inoculated mares had a CTUP > 1.0 cm by 5-day post-inoculation. By performing both tests, 20 of 22 mares were correctly identified with respect to pregnancy outcome. However, three inoculated mares exhibited minimal clinical signs and likely would not be examined in a clinical setting. These tests were diagnostic for identifying fetoplacental compromise in the mare.

© 2006 Elsevier Inc. All rights reserved.

Keywords: Mare; Pregnancy; Placentitis; Ultrasonography; Progesterins

* Corresponding author. Tel.: +1 859 233 0371; fax: +1 859 255 5367.

E-mail address: Mleblanc@roodandriddle.com (M.M. LeBlanc).

1. Introduction

Placentitis caused by bacteria ascending through the caudal genital tract is a common cause of abortion, premature birth and foal death in the first 24 h of life [1,2]. *Streptococcus equi* subspecies *zooeconomicus* is the bacteria most commonly isolated [1]. The ability to diagnose mares with fetoplacental compromise due to placentitis, colic, uterine torsion or laminitis would benefit veterinarians and horse owners as early identification and treatment of an afflicted mare may result in the birth of a viable foal. Furthermore, mares identified at risk for abortion could be monitored closely for possible dystocia, premature delivery or premature placental separation. Diagnostic tools used to identify mares at risk of premature delivery include transabdominal and transrectal ultrasonography of the uterus and its contents [3–6], and measurement of maternal progestins, total estrogens and estrone sulphate [7]. As a single test, none of these methods accurately diagnoses fetoplacental compromise; however, combining two or more techniques may improve detection rates.

Transrectal ultrasonography identifies mares that have uteroplacental thickening or placental separation in the caudal uterine body, the area most often affected in ascending placentitis [5,8]. The combined thickness of the uterus and placenta (CTUP), measured by transrectal ultrasonography, increases from 0.6 cm at 7 months of gestation to 1.0–1.2 cm at term [5,6]. A CTUP > 1.2 cm at 11 months and 1.5 cm at 12 months is suggestive of a placental abnormality [6,8–10]. Transrectal ultrasonographic data on mares suspected of having placentitis are limited to a case report and two field studies [8–10]. Unfortunately, placental histology was not available in the field studies, so relationships between uteroplacental thickening and inflammation of fetal membranes were not assessed.

The maternal plasma progestin profile in the mare is unique as compared to ruminants or humans [11]. Maternal progestin concentrations are stable from approximately Days 150–315 and then begin to rise dramatically, with concentrations declining precipitously in the last 1–2 d before delivery. During the second half of pregnancy, progestins are synthesized by the fetus and uteroplacental tissues [11], with the fetus synthesizing large quantities of pregnenolone, the precursor for all the progestins [11,12]. Maternal plasma progestin concentrations in mid- to late gestation can be assayed with progesterone RIAs and ELISAs because the progesterone antibody used in these assays cross reacts with a number of the progestins

produced by the fetoplacental unit [11]. Concentrations of plasma progestins from Days 200 to 305 measured by progesterone RIAs or ELISAs ranged from 1 to 10 ng/mL in horse mares and from 3 to 16 ng/mL in pony mares with uncompromised pregnancies [11–15]. Maternal plasma progestin concentrations do not fluctuate in late gestation. Plasma progestin concentrations varied by <15% within a 24 h period when blood was collected every 15 min for the 2 h surrounding sunrise and sunset every sixth day from Day 310 until parturition (Sheerin B and LeBlanc M, unpublished data). Previous studies have suggested that maternal plasma progestin concentrations may be indicative of fetoplacental health [13–15]. Two abnormal progestin patterns have been described in mares with compromised pregnancies. In acute conditions that result in abortion (e.g. uterine torsion or colic), progestins tend to decline hours or days before abortion [15–18]. In chronic conditions (e.g. placentitis, twins, or chronic laminitis) or after a stress such as prolonged travel (M. LeBlanc unpublished data) or subjection to low flying jet noise, maternal plasma progestins may elevate significantly, sometimes for several weeks before abortion or premature delivery of a viable foal. If the stress is removed promptly, progestin concentrations may return to normal, resulting in an uneventful foaling at term [13–15,19].

The accuracy of identifying fetoplacental compromise by transrectal ultrasonography and plasma progestin profiles is not known. Nor is it known what percentage of mares with placentitis exhibit clinical signs, have abnormal transrectal ultrasonographic findings, or experience changes in progestin concentrations. We have reported previously that ascending placentitis induced experimentally by infusion of an inoculum of *S. equi* subspecies *zooeconomicus* into the cervix may result in thickening of the uteroplacental tissue in the region of the cervical star, fetal compromise, a change (increase or decrease) in maternal plasma progestin concentrations, and premature delivery [14,20–22]. The objective of this study was to determine the accuracy of transrectal ultrasonographic examination of the caudal uterus and an abbreviated progestin profile in identifying fetoplacental compromise in mares with experimentally induced placentitis. This study was part of a large experiment designed to identify the mechanism through which placentitis causes premature labor. Information on immunological profiles and myoelectrical activity in surgically instrumented mares and detailed microbiological and pathological findings are not addressed here, but are the subject of other reports.

2. Materials and methods

2.1. Experimental animals

Over the years 1999–2001, 22 pregnant pony mares (250–350 kg) were allocated into four groups: (1) control ponies ($n = 5$); (2) control ponies instrumented with myometrial electrodes via laparotomy ($n = 2$); (3) inoculated instrumented ponies ($n = 11$); (4) inoculated ponies ($n = 4$). Mares were maintained at pasture or in stalls after surgical instrumentation at the College of Veterinary Medicine, University of Florida. Pregnancy was confirmed by ultrasonographic examination of the reproductive tract. Mares received normal health care as dictated by the Equine Research Protocol of the College. In addition, mares were vaccinated during the fifth, seventh and ninth months of pregnancy to prevent abortion due to equine herpes virus 1. This project was approved by the Institutional Animal Care and Use Committee (A350) at the University of Florida.

Methodology for instrumentation has been described previously [20]. Briefly, instrumentation consisted of general anesthesia and ventral laparotomy to place myometrial leads on the uterus ($n = 13$; Groups 2 and 3) and to insert allantoic catheters ($n = 4$; Group 3, mares 4, 5, 9, 11; Table 1). The allantoic catheters and myometrial electrodes were sutured onto the uterine serosa, passed through the abdominal wall in the flank region, tunneled through the subcutaneous space and brought out over the back near the withers. Allantoic catheters were maintained in a sterile plastic bag contained in a catheter pouch sewn to the mare's back. Each aliquot of allantoic fluid collected was cultured for the presence of aerobic bacteria. Antibiotics and flunixin meglumin were given at the appropriate intervals for 4–6 d after surgery, depending on the mare's response to instrumentation. Altrenogest (Regumate, Intervet, Millsboro, DE, USA), an oral progestin was also given (0.0088 mg/kg of body weight) for 7 d.

2.2. Bacterial inoculation

The inoculum consisted of a single stock solution of 1×10^9 colony forming units (CFU)/mL *S. equi* subspecies *zooepidemicus*, prepared as previously described [20]. It was divided into 2.5 mL aliquots, stored in vials at -70°C , and thawed before use. It was obtained from a clinical case of equine endometritis submitted to the Microbiology Laboratory of the College of Veterinary Medicine, University of Florida. An inoculum was prepared by diluting the stock solution with sterile saline to yield 1×10^8 CFU in a

Table 1

Outcome of 15 mares that received an intra-cervical inoculation of bacteria and the associated changes in the abbreviated progestin profile and transrectal ultrasonographic examination of the caudal uterus

Mare ID ^a	Interval from inoculation to parturition (d) ^b	Change in progestin profile ^c	CTUP increased/or separation ^d
Group 3			
1	4 (Day 297)	D	No
2	5 (Day 289)	D	No
3	5 (Day 286)	D	Yes
4*	6 (Day 294)	D	Yes
5*	6 (Day 293)	D, I, D	Yes
6	7 (Day 284)	D	Yes
7	15/8 ^b (Day 285)	I	Yes
8	16 (Day 297)	N/C	Yes
9 ^{e*}	20/10 ^b (Day 309)	I	No
10 ^c	22 (Day 313)	N/C	No
11*	27/16 ^b (Day 314)	I	No
Group 4			
12	6 (Day 296)	D	No
13	9 (Day 296)	I	Yes
14	12 (Day 298)	I	Yes
15	15 (Day 306)	I	Yes

^a Group 3 mares were instrumented with myometrial electrodes; four mares* (nos. 4, 5, 9 and 11) were fitted with allantoic catheters in addition to the myometrial electrodes; Group 4 mares only received intra-cervical inoculations.

^b Three mares, nos. 7, 9 and 11, received two inoculations (7, 10 and 11 d, respectively, after first inoculation); days from second inoculation to parturition are shown after the /. Day of gestation that mare delivered is shown in parentheses.

^c Change is defined as an increase (I) or decrease (D) in progestin concentration in Samples 2, 3, or 4 by >50% of Sample 1 obtained before inoculation. The second, third and fourth blood samples were obtained 2, 4, and 6 d after inoculation.

^d Placental thickening is defined as a CTUP > 1.0 cm before Day 320 of gestation.

^e Delivered live, viable, precociously mature foal.

volume of 1 mL. For inoculation, the tail of the mare was wrapped, the perineum washed thoroughly and a sterile artificial insemination pipette was introduced into the vagina by an operator wearing a sterile glove and sleeve. A portion of the cervical plug was removed and the inoculum deposited approximately 2 cm into the cervix. A second syringe with 6 mL of air was used to evacuate the pipette before it was withdrawn.

The inoculation dose was determined in preliminary trials. Group 3 mares received 1×10^8 CFU of *S. equi* subspecies *zooepidemicus* because mares exhibited no signs of infection within 14 days when inoculated with lower doses. Group 4 mares received 1×10^7 CFU of bacteria because two mares aborted within 3 d of receiving 1×10^8 CFU of *S. equi* subspecies *zooepi-*

demicus. Group 3 mares were inoculated between Days 277 and 293 of gestation (Weeks 40–42), ≥ 14 d after instrumentation. Three mares in Group 3 (mares 7, 9 and 11; Table 1) were inoculated a second time 7–11 d after the first inoculation because they did not exhibit clinical signs of infection. Group 4 mares were inoculated between Days 286 and 290 (Week 41).

2.3. Examination protocols

Physical examinations were performed weekly in all mares beginning on Day 255. After instrumentation (Groups 2 and 3), inoculation (Group 4) or Day 320 (Group 1), examinations were performed daily until parturition. Examinations included determination of vital signs, evaluation of the perineum for exudate and the mammary gland for premature development. Vulvar exudate was graded on a scale of 0–3 as follows: 0 = no exudate; 1 = scant exudate in vestibule; 2 = exudate on vulvar lips; 3 = exudate on hind legs. Mammary gland development was graded on a scale of 0–4 as follows: 0 = no development; 1 = slight filling; 2 = filling of both halves but no milk upon expression; 3 = moderately filled mammary glands from which milk could be expressed; 4 = full mammary gland with milk dripping from the teats. Fetal membranes were grossly evaluated within 3 h of delivery and five tissue samples, two from the cervical pole, one from the uterine body, and one from each horn were placed in formalin and submitted for histological evaluation.

2.4. Transrectal ultrasonography

The transrectal ultrasonographic technique was performed as previously described using a 5–7.5 mHz linear transrectal probe attached to a Microimager 1000/VFI (Impact; Ausonics, Santa Clara, CA, USA) in 1999 and an Aloka 900 (Aloka; Wallingford CT, USA) in 2000 and 2001 [21]. Ultrasonographic examinations were performed at approximately weekly intervals from Day 265 until parturition in control ponies (Groups 1 and 2) and weekly from Day 265 until surgery or inoculation in Groups 3 and 4. Thereafter, examinations were performed several times weekly until abortion or parturition in Groups 3 and 4. Several measurements of combined thickness of the uterus and placenta (CTUP) were obtained at each examination, an average was calculated and a mean CTUP for each week of gestation obtained. A mean CTUP > 1.0 cm on an examination day (before Day 320) or placental separation were considered abnormal and used as a positive indication of fetoplacental compromise.

2.5. Measurement of plasma progesterin concentrations

A jugular blood sample was obtained weekly from all mares from Day 240 to 265 at 0800 h. Beginning on Day 266, a jugular blood sample was obtained daily from Groups 2 to 4 and thrice weekly from Group 1 mares at 0800 h until parturition. Blood was placed immediately on ice, plasma harvested by centrifugation within 20 min of collection and stored at -20°C until assayed. Progesterins were measured in duplicate using a commercial solid phase I^{125} radioimmunoassay kit (#TKPG5; Coat-A-Count, Diagnostic Products Corporation, Los Angeles, CA, USA) previously validated in our laboratory for cross reactivity to 10 progesterins produced by the fetoplacental unit [23]. Cross-reactivity of the progesterone antibody with progesterins produced by the fetoplacental unit was: 5α -pregnane-3, 20-dione: 10% (major steroid in fetal umbilical vein and present in maternal plasma); 3α -hydroxy- 5α -pregnane-20-one: 0.5% (present in fetal umbilical artery); 20α -hydroxy- 5α -pregnane-3-one: 0.25% (major steroid in maternal plasma). Cross reactivity with the other seven metabolites produced by the fetoplacental unit was not detected [23]. The inter- and intra-assay coefficients of variation were 8.1 and 5.0%, respectively.

Profiles of maternal plasma progesterin concentrations for each mare were plotted against day of gestation to identify patterns. Plots were analyzed visually to determine the number of samples and the interval between samples that would most likely enable identification of fetoplacental compromise after bacterial inoculation (Fig. 1). An abbreviated plasma progesterin profile that consisted of four blood samples obtained at 48-h intervals was created. The first blood sample was obtained immediately before inoculation in Groups 3 and 4 with remaining samples obtained 2, 4, and 6 d after inoculation. The first blood sample used for the profile in Groups 1 and 2 was obtained on Day 285, the mean day before inoculation for inoculated mares with three additional samples obtained on Days 287, 289, and 291. A plasma progesterin profile was considered to be abnormal if the second, third or fourth value increased or decreased by more than 50% of the first value (Fig. 1). In the three mares that were inoculated twice, change in the progesterin profile was measured after the second inoculation.

2.6. Statistical analysis

All data are expressed as means \pm S.E.M. Plasma progesterin data were placed into four periods (basal,

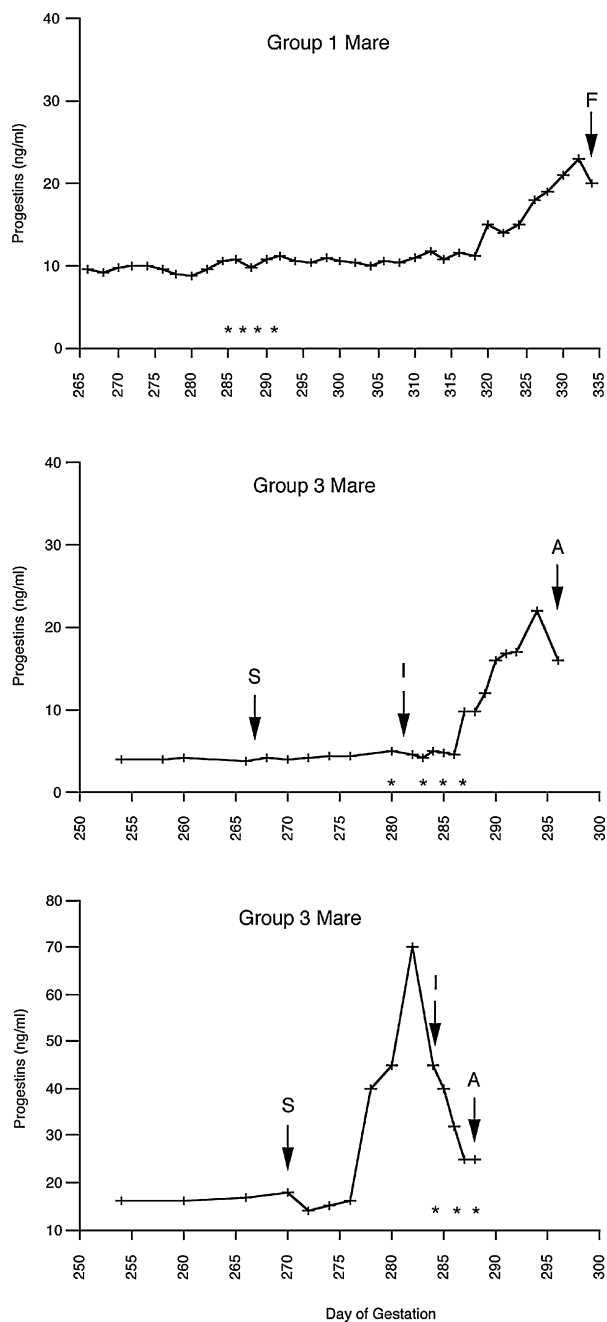


Fig. 1. Examples of plasma progesterone profiles from a Group 1 mare (Panel A); a Group 3 mare that exhibited an increase in plasma progesterone after instrumentation (Panel B) and a Group 3 mare that exhibited an increase in plasma progesterone after inoculation (Panel C). Abbreviations—F: foaling; S: instrumentation; I: inoculation; A: abortion. (*) mark the four sample dates for the abbreviated plasma progesterone profile. Note that the x-axis of Panel A differs from that of Panels B and C.

post-surgical, post-inoculation and delivery) in order to compare mare groups across days of gestation and to identify differences in profiles. Basal period included all blood samples collected before Day 266 in Groups 1 and 4 and all blood samples collected before instrumentation in Groups 2 and 3. Post-instrumentation period included all blood samples obtained from surgery to inoculation in Groups 2 and 3 and all blood samples obtained between Day 266 and 284 in Groups 1 and 4. Post-inoculation period included all blood samples obtained from inoculation until 3 days before parturition in Groups 3 and 4 and all blood samples obtained from Day 286 to 305 in Groups 1 and 2. Delivery period included the last three samples obtained in the 72 h before parturition from all mares.

Transrectal ultrasonographic data (CTUP) were analyzed by least-squares analysis of variance using the Proc GLM procedure of SAS [24]. The model included effects of inoculation (yes or no), surgery (yes or no), inoculation \times surgery, pony (inoculation \times surgery), week of gestation, week \times inoculation, week \times surgery, week \times inoculation \times surgery and year.

Sensitivity (true positives) and specificity (true negatives) were calculated to determine the ability of transrectal ultrasonography (CTUP > 1.0 cm before Day 320 or placental separation) and the abbreviated progesterone profile (50% change from Sample 1) to differentiate ponies with fetoplacental compromise after inoculation from control ponies [25]. Changes in the abbreviated progesterone profile were recorded after the second inoculation in mares 7, 9 and 11. No fetoplacental compromise (no disease) was defined as delivery of a healthy foal after Day 320 with fetal membranes having no gross or histological signs of placentitis. Fetoplacental compromise (disease) was defined as birth of a non-viable, premature fetus or the birth of a precociously mature foal before Day 316 in combination with histological evidence of inflammation in fetal membranes. Placentitis was confirmed by gross and histological evaluation of fetal membranes by a board-certified veterinary pathologist. Predicted positive and negative values were calculated to determine the likelihood the test accurately identified the ponies' condition. Positive predictive value was defined as the proportion of animals that tested positive that truly were affected. Negative predictive value was defined as proportion of animals that tested negative that were truly unaffected. Categorical data were analyzed by the Fisher Exact test in order to determine if more treatment mares (Groups 3 and 4) had placental separation and a CUTP that exceeded 1.0 cm before Day 320 than

control mares, and to determine if more treatment mares exhibited a change in the abbreviated progestin profile than control mares.

3. Results

3.1. Outcome and clinical finding

Group 1 mares delivered viable healthy foals between Days 330 and 350. One Group 2 mare experienced a dystocia (malpresentation of the front limb) on Day 340 and the foal died shortly after birth. Fetal membranes from control mares had no gross or histological lesions. Group 3 and 4 mares aborted ($n = 13$) or foaled precociously mature, viable foals ($n = 2$) between Days 297 and 314 (Table 1). The interval from inoculation (from second inoculation in three mares) to parturition was 4–22 d. Fetal membranes from all inoculated mares had gross and/or histological lesions within the chorioallantois that were restricted to the cervical star region, with one exception (mare 10 had a second lesion in the uterine body at the base of the left horn; a nocardioform bacteria was isolated). Gross lesions included thickening, necrosis and discoloration and in some mares, a mucoid exudate over the cervical star of the chorioallantois. The final histological diagnosis for 13 of 15 inoculated mares was bacterial, necrotizing, placentitis. Histological diagnosis for the remaining two mares was chorionitis (mare 3) and squamous metaplasia of the chorion in the area of the cervical star (mare 11). Detailed descriptions of the histological and microbiological findings are presented elsewhere [22].

Control mares did not exhibit a vulvar discharge before parturition. Nine of 13 inoculated mares had a vulvar discharge score of two or greater by the second ($n = 7$) to fifth day ($n = 2$) post-inoculation. Vulvar discharge was inconsistent and scores were less than two in the remaining four mares (mares 1, 3, 6 and 10). Mammary gland score was 0 in all mares before inoculation; it increased to ≥ 3 in only five inoculated mares. Once the udder developed it did not wane but remained consistent or progressed to a higher score. Mammary gland development progressed slowly over the last 3 weeks of gestation in control mares and none dripped milk before parturition.

3.2. Plasma progestin concentrations

Plasma progestin concentrations were stable in the basal period, ranging from 4.2 to 16 ng/mL (mean, 8.1 ± 2.1). Plasma progestin concentrations in Group 1

and 2 mares began to rise 20 d before parturition and peaked at 20.5 ± 5.9 ng/mL directly before parturition (Fig. 1). All inoculated mares had abnormal profiles. Group 3 mares exhibited two patterns after instrumentation and inoculation (Fig. 1 and Table 1). Six mares in Group 3 exhibited a rise in progestins after instrumentation (basal concentration of Group 3 mares: 8 ± 1.3 ng/mL; six mares after instrumentation: 14.42 ± 0.8 ng/mL). Concentrations remained elevated at inoculation and then declined rapidly (concentration at inoculation: 15.9 ± 2.34 ng/mL; concentration at delivery 10 ± 1.6 ng/mL). Progestin concentrations in the remaining five Group 3 mares were stable until after inoculation when concentrations began to rise and continued to rise until delivery (basal progestin concentrations: 8 ± 1.3 ng/mL; after instrumentation 10 ± 0.8 ng/mL; delivery: 20.6 ± 1.8 ng/mL). Plasma progestin concentrations rose in three Group 4 mares and decreased in one mare after inoculation (Table 1).

No control mares exhibited a change in the abbreviated progestin profile whereas 13 of 15 inoculated mares exhibited either a decrease or increase (Fig. 1 and Table 1). Mares that aborted within 7 d exhibited a decrease in progestin concentrations while mares that sustained pregnancy for more than 8 d exhibited an increase. Mares 8 and 10 (Group 3) were not identified as having a compromised pregnancy by the abbreviated progestin profile. Both mares exhibited a rise in progestins after the last sample in the abbreviated profile was obtained.

3.3. Transrectal ultrasonographic findings

Transrectal CTUP was affected by gestational age ($P < 0.05$); it increased from 0.68 ± 0.01 cm at Day 265 (Week 37) to 1.10 ± 0.16 cm by Day 345 (Week 49) in control mares (Fig. 2). There was an interaction between inoculation and gestational age ($P < 0.03$) with transrectal CTUP increasing after inoculation in Groups 3 and 4 as compared to values for Groups 1 and 2. Before inoculation, transrectal CTUP ranged from 0.45 ± 0.06 to 0.72 ± 0.04 cm and after inoculation ranged from 0.43 to 3.1 cm. Instrumentation did not affect CTUP.

The CTUP increased to >1.0 cm in nine of 15 inoculated mares 3–5-d post-inoculation and in five of seven control mares after Day 320. No control mares had placental separation. Two of four (50%) mares in Group 4 and seven of 11 (64%) mares in Group 3 exhibited placental separation on transrectal ultrasonographic images (Fig. 3). One of six inoculated mares not exhibiting placental separation or thickening (mare 11)

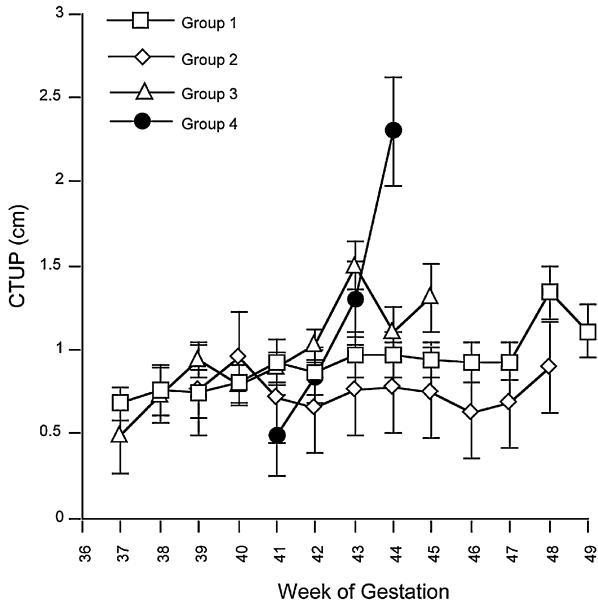


Fig. 2. Combined thickness of the uterus and placenta (CTUP) in mares from Week 37 (265 d) until parturition (345 d). There was an effect of gestational age on CTUP ($P < 0.05$) in Groups 1 and 2 and an interaction between inoculation and gestational age in Groups 3 and 4 ($P < 0.03$). Group 3 mares were inoculated between Weeks 40 and 42 (Days 277–293); Group 4 mares were inoculated in Week 41 (Days 286–290).

had hyperechoic amniotic fluid and delivered a septic, nonviable foal 16 days after the second inoculation (Fig. 4). Examination of the fetal membranes revealed squamous metaplasia in the cervical star area.

3.4. Diagnostic efficiency of abbreviated plasma progesterin profile and transrectal ultrasonography

More Group 3 and 4 mares had abnormal transrectal ultrasonography findings and exhibited a change in the abbreviated plasma progesterin profile than Group 1 and 2 mares ($P = 0.007$, $P < 0.001$, respectively; Table 2). No control mares (Groups 1 and 2) exhibited a change in the abbreviated progesterin profile nor did they exhibit a CTUP > 1.0 cm before Day 320 or placental separation before parturition. Thirteen of 15 inoculated mares were identified as having fetoplacental compromise by the abbreviated progesterin profile and nine of 15 were identified by transrectal ultrasonography. The accuracy of the two diagnostics in differentiating mares with ascending placentitis from those mares without ascending placentitis is presented in Table 2.

By performing both transrectal ultrasonographic examinations and an abbreviated plasma progesterin profile, 14 of 15 mares with fetoplacental compro-

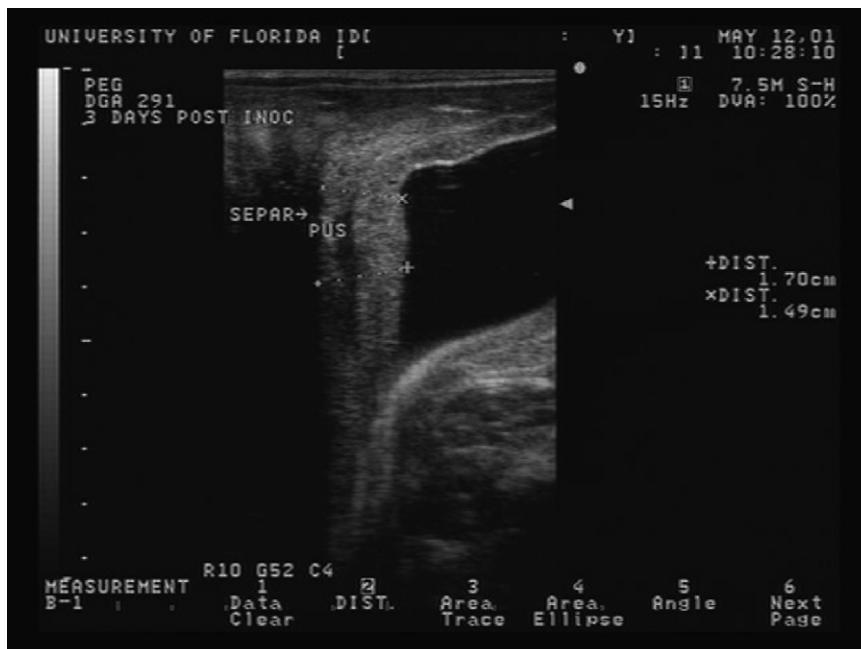


Fig. 3. Ultrasonographic image of the caudal aspect of the uterus in a mare 3 d after inoculation. The calipers measured the combined thickness of the uterus and placenta (CTUP). The distance between the two sets of calipers is 1.7 and 1.49 cm. The chorioallantois has separated from the endometrium. Abbreviations: SEPAR—marks area of separation; Exudate (pus) is present between the endometrium and chorioallantois. The fetal head is in contact with the chorioallantois in the lower right portion of the image.

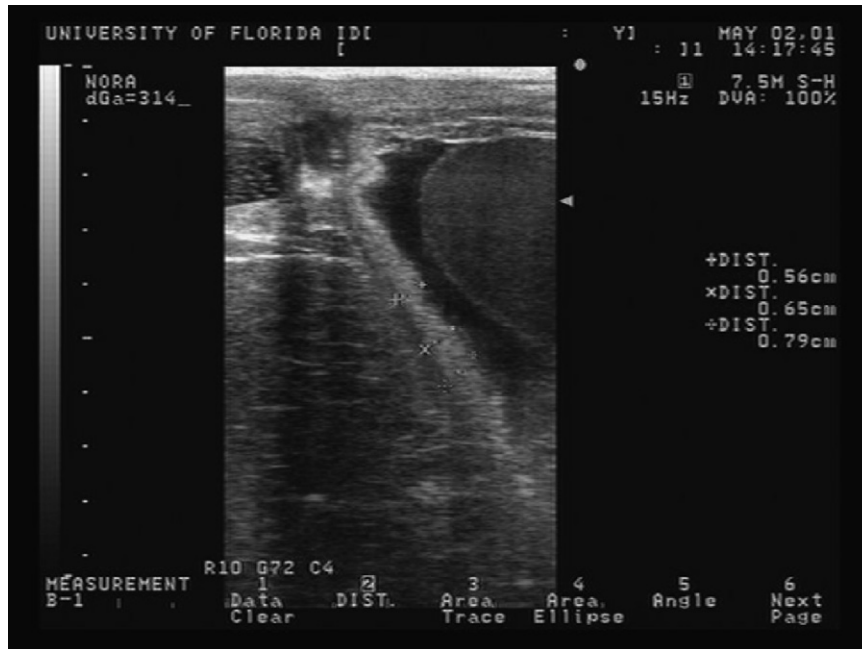


Fig. 4. Ultrasonographic image of the caudal aspect of the uterus in a mare on Day 314, 16 d after the second inoculation. The CTUP in the ventral aspect of the uterus was 0.56, 0.65 and 0.79 cm. No placental separation was observed. Arrow points to hyperechoic amniotic fluid. The mare delivered a septic, nonviable foal 9 h after the image was taken.

mise after inoculation were identified (measurements obtained after second inoculation in mares 7, 9 and 11) and six of seven control mares were recognized as carrying normal pregnancies (Table 2). Mare 10 (Group 3) and one control mare (Group 1) were not classified correctly. Maternal progesterin concentration of mare 10 rose 24 h after the last progesterin sample included in the profile was obtained. The control mare not correctly identified experienced a dystocia unrelated to placental status and the foal died shortly after birth.

4. Discussion

4.1. Outcome

The response of mares to the bacterial inoculation varied greatly, with abortion or delivery occurring in 4–22 d. Two mares delivered precociously mature foals whereas 13 aborted. Differences in response may be related to innate immunity, age, amount of cervical plug removed at inoculation, frequency of previous immune responses to *S. equi* subspecies *zooepidemicus*, and

Table 2

Ability of transrectal ultrasonography or an abbreviated plasma progesterin profile to differentiate mares with ascending placentitis from those mares without ascending placentitis^a

	Sensitivity (%)	Specificity (%)	Predicted positive (%)	Predicted negative (%)
Transrectal ultrasonographic findings ^b	60, 9/15	100, 7/7	100, 9/9	61, 7/13
Change in progesterin ^c	87, 13/15	100, 7/7	100, 13/13	78, 7/9

^a Placentitis was confirmed by gross and histological evaluation of fetal membranes and culture of fetal stomach contents in non-viable foals. Fetal membranes were evaluated histologically in all mares to determine the presence or absence of placentitis.

^b Placental separation and thickening were indicative of disease. Placental thickening was defined as a combined thickness of the uterus and placenta (CTUP) > 1.0 cm before Day 320.

^c A change in the abbreviated progesterin profile was defined as an increase or decrease in the progesterin concentration of Samples 2, 3, or 4 by >50% of the progesterin concentration in Sample 1 obtained directly before inoculation. Samples for the progesterin profile were obtained after the second inoculation in mares 7, 9 and 11. Plasma progesterin concentrations from Groups 1 and 2 included the blood sample collected on Day 285, the mean day before inoculation in Groups 3 and 4 and three additional samples taken on Days 287, 289, and 291.

possible changes in the immune system associated with instrumentation. Mares in Group 3 received a 10-fold higher dose of bacteria than mares in Group 4, yet three mares in Group 3 maintained pregnancy longer and three required a second inoculation to produce clinical signs of infection (Table 1). Lack of response to a single bacterial challenge has been observed previously in instrumented primates in a model of chorioamnionitis where immunological and clinical responses were induced in some females only after a second inoculation (M. Gravett, personal communication). Removal of the cervical plug was critical to inducing infection in our model. Little is known about the contents of the cervical plug in the mare, whether it has bactericidal properties or what causes some mares to lose it prematurely.

Clinical signs of infection were inconsistent. Four inoculated mares exhibited no clinical signs, even though each mare was meticulously observed for vaginal discharge by lifting the tail and spreading the vulva lips. Although accurate, this method is not practical and would not be performed routinely in large breeding farms.

As allantoic catheters may have served as a portal of entry for bacteria, allantoic fluid was cultured when obtained and the mare's skin underneath the catheter bag was swabbed weekly. *S. equi* subspecies *zooepidemicus* was the only bacteria isolated and then from only two allantoic samples obtained in the 24 h preceding abortion. It was never isolated from skin swabs. We propose that bacteria entered fetal fluids through the chorioallantois in the area of the cervical star after inoculation. Evidence to support this hypothesis included: (1) mares with allantoic fluid catheters exhibited changes in progesterin profiles days before bacteria were isolated; (2) cocci were present in histological sections of chorioallantois in the region of the cervical star; (3) no bacteria were present in histological sections of chorioallantois surrounding the catheter exit site.

4.2. Plasma progesterin profiles

Mares in this study had abnormal progesterin profiles after inoculation, a finding previously reported in mares with fetoplacental compromise [13–18]. Mares that aborted within 7 d exhibited a decrease in plasma progesterins whereas mares that maintained pregnancy for more than 8 d, exhibited a rise. Abnormal maternal progesterin patterns may be associated with type and degree of stress, e.g. hypoxia during instrumentation (increase in progesterin concentration); combination of stresses, e.g. instrumentation and inoculation (increase

then decrease in progesterin concentration); or differences in the ability of the immune system to handle bacteria, e.g. rise or fall in progesterins in mares inoculated with similar doses of bacteria. Similar to results of Rosedale and coworkers [13], two viable foals were born prematurely from 15 inoculated mares. Data from both studies suggested that a premature increase in maternal plasma progesterins may indicate accelerated fetal maturation or fetal stress and that fetal adrenal glands appear to be involved in progesterin synthesis.

Maternal progesterin profiles may be affected by surgical or medical disease. Santschi et al. [17,26] reported a decrease in progesterin concentrations in six of 22 mares admitted to a hospital with surgical or medical colic. Five of the six mares subsequently aborted. Two of the five mares that aborted were within 60 d of foaling and experienced hypoxia during colic surgery. In this study, progesterins rose after instrumentation in 6 of 13 instrumented mares. Concentrations remained elevated at inoculation, 14–18 d after instrumentation and then declined rapidly. These six mares had mean facial arterial pressure below 70 mm Hg for more than 70 min during surgery. Therefore, placental blood flow may have been compromised during instrumentation as equine maternal hypoxemia is known to cause an immediate decrease in umbilical vein oxygen pressure [27]. Aorto-caval compression, a possible side effect of positioning on the surgical table, may have contributed to uterine hypoperfusion. Response to instrumentation combined with inoculation likely influenced time to abortion. These findings suggest that changes in maternal progesterins in mares after surgery may be associated with fetoplacental compromise, especially if the surgical procedure is more than 60 min, the mare experiences periods of low oxygen tension or there are additional stresses.

4.3. Transrectal ultrasonographic findings

Transrectal ultrasonographic examination of the caudal uterus identified changes in the CTUP and placental separation in nine of 15 inoculated mares. Of the six mares not identified, three aborted within 7 d; therefore, gross placental changes may not have developed. The remaining three mares (mares 9, 10 and 11) not identified had chronic placentitis. Mare 11 had hyperechoic amniotic fluids (Fig. 4), but the relevance of that observation was not realized until after abortion.

Mean CTUP measurements of our control ponies (evaluated from Day 265 until parturition) were slightly higher than that reported by Barnes et al. [28] who

measured CTUP in pony mares, but were lower than that reported for horse mares by Bucca [6] who evaluated 150 Standardbred mares from 6 to 12 months of gestation but similar to measurements presented by Renaudin et al. who evaluated 10 Quarter Horse mares [5]. Slight increases in CTUP should be interpreted with caution as mares carrying normal pregnancies may be misdiagnosed with ascending placentitis.

Placental thickening and separation were first visualized 3–5 d after inoculation. This contrasts with Renaudin et al. [7] who observed placental thickening on transrectal ultrasonography in a mare 7 h after intra-cervical inoculation with 5×10^6 CFU of *S. zooepidemicus* on Day 350. Differences may be attributed to day of gestation inoculation was performed (mean day of inoculation in this study was Day 285), degree of cervical relaxation, possible loss of the cervical plug in the mare inoculated on Day 350 and volume of the inoculum (30 mL in mare on Day 350 versus 1 mL in our study).

Our study suggested that mares clinically affected with ascending placentitis may require two or more transrectal ultrasonographic examinations of the caudal uterus performed 3–5 d apart in order to identify placental separation or thickening. Mares with placentitis that abort within 7 d may not be identified because placental thickening or separation may not have occurred. Clarity of fetal fluids should be evaluated, as cloudy fluid may be the only abnormality visualized (Fig. 4).

4.4. Accuracy of abbreviated progestin profile and transrectal ultrasonography in identifying fetoplacental compromise

Twenty of 22 mares were identified correctly when both diagnostic tests were used. We elected to measure changes in maternal progestins after the second inoculation in three mares (mares 7, 9 and 11) because they had no clinical signs after the first inoculation (infection may not have been established). If the progestins were measured after the first inoculation, sensitivity and specificity would be less as mares 9 and 11 would not have been classified as abnormal (Table 1). Although the tests indicated that all control mares were carrying normal pregnancies, one foal died after dystocia. These diagnostics cannot identify perinatal asphyxia associated with difficult birth. After Day 305, the abbreviated progestin profile should only be used to identify a decrease in progestins, as concentrations normally rise in the last 3 weeks of gestation.

5. Conclusions

In conclusion, an abbreviated progestin profile and transrectal ultrasonography of the caudal uterus identified mares with fetoplacental compromise associated with ascending placentitis. More affected mares were identified by changes in the abbreviated progestin profile than by measurement of CTUP. In clinical practice, measurement of plasma progestins are useful if results can be obtained quickly and compared to an established range of normal values. An abbreviated plasma progestin profile can be used to identify mares with a compromised fetoplacental unit after a surgical procedure or medical crisis. Pregnancies of valuable mares or mares that have experienced placentitis previously can be monitored by measuring plasma progestins or CTUP either bi-weekly or monthly from mid-to late gestation. Mares with values that deviate from the norm can be evaluated further by physical examination, repeated transrectal measurements of CTUP and plasma progestin concentrations to determine the course of therapy.

Acknowledgements

This work was supported by the Grayson Jockey Club, the Dorothy Havemeyer Foundation, and the State of Florida pari-mutuel wagering trust. The authors thank Drs. Kevin Anderson, Guy Lester and Shannon Luznar for technical assistance and Dr. Maron Calderwood Mays for interpretation of the histological specimens.

References

- [1] Giles RC, Donahue JM, Hong CB, Tuttle PA, Petrites-Murphy MB, Poonacha KB, et al. Causes of abortion, stillbirth, and perinatal death in horses: 3527 cases (1986–1991). *J Am Vet Med Assoc* 1993;203:1170–5.
- [2] Hong CB, Donahue JM, Giles RC, Petrites-Murphy MB, Poonacha KB, Roberts AW, et al. Etiology and pathology of equine placentitis. *J Vet Diag Invest* 1993;5:56–63.
- [3] Reef VB, Vaala WE, Leila TW, Spencer PA, Hammet B. Ultrasonographic evaluation of the fetus and intrauterine environment in healthy mares during late gestation. *Vet Radiol Ultrasound* 1995;36:533–41.
- [4] Reef VB, Vaala WE, Worth LT, Sertich PL, Spencer PA. Ultrasonographic assessment of fetal well-being during late gestation: development of an equine biophysical profile. *Equine Vet J* 1996;28:200–8.
- [5] Renaudin CD, Troedsson MHT, Gillis CL, King VL, Bodena A. Ultrasonographic evaluation of the equine placenta by transrectal and transabdominal approach in the normal pregnant mare. *Theriogenology* 1997;47:559–73.

- [6] Bucca S. Assessment of feto-placental well-being in the mare from mid-gestation to term: transrectal and transabdominal ultrasonographic features. *Theriogenology* 2005;64:542–57.
- [7] LeBlanc MM. Identification and treatment of the compromised equine fetus: a clinical perspective. *Equine Vet J* 1997;Suppl 24:100–3.
- [8] Renaudin CD, Troedsson MHT, Schrenzel MD. Transrectal ultrasonographic diagnosis of ascending placentitis in the mare: a report of two cases. *Equine Vet Ed* 1999;11:69–74.
- [9] Troedsson MHT, Zent WW. Clinical ultrasonographic evaluation of the equine placenta as a method to successfully identify and treat mares with placentitis. In: *Proceedings of a workshop on the equine placenta*; 2004. p. 66–7.
- [10] Troedsson MHT, Renaudin CD, Zent WW, Steiner JV. Transrectal ultrasonography of the placenta in normal mares and in mares with pending abortion: a field study. In: *Proceedings of the 43rd annual convention of the American association of equine practitioners*; 1997. p. 256–8.
- [11] Ousey JC. Periparturient endocrinology in the mare and foetus. *Repro Domestic Anim* 2004;39:222–37.
- [12] Ousey JC, Forhead AJ, Rosedale PD, Grainger L, Houghton E, Fowden AL. Ontogeny of uteroplacental progesterone production in pregnant mares during the second half of gestation. *Biol Reprod* 2003;69:540–8.
- [13] Rosedale PD, Ousey JC, Cottrill CM, Chavatte P, Allen WR, McGladdery AJ. Effects of placental pathology on maternal plasma progesterone and mammary secretion calcium concentration and on neonatal adrenocortical function in the horse. *J Reprod Fertil* 1991;44(Suppl):579–90.
- [14] Stawicki RJ, Reubel H, Hansen PJ, Sheerin BR, O'Donnell LJ, Lester GD, et al. Endocrinological findings in an experimental model of ascending placentitis in the mare. *Theriogenology* 2002;58:849–52.
- [15] Ousey JC, Houghton E, Grainger L, Rosedale PD, Fowden AL. Progesterone profiles during the last trimester of gestation in Thoroughbred mares with normal or compromised pregnancies. *Theriogenology* 2005;63:1844–56.
- [16] van Niekerk CH, Morgenthal JC. Fetal loss and the effect of stress on plasma progesterone levels in pregnant Thoroughbred mares. *J Reprod Fertil* 1982;32(Suppl):453–7.
- [17] Santschi EM, LeBlanc MM, Weston PG. Progesterone, oestrone sulphate and cortisol concentrations in pregnant mares during medical and surgical disease. *J Reprod Fertil* 1991;44(Suppl):627–34.
- [18] Ousey JC, Cash RSG, Rosedale PD, Worthy K. Plasma concentrations of progesterone, oestrone sulphate and prolactin in pregnant mares subjected to natural challenge with equid herpesvirus-1. *J Reprod Fertil* 1987;35(Suppl):519–28.
- [19] LeBlanc MM, Lombard C, Massey R, Klapstein E, Lieb S. Behavioral and physiological responses of horses to simulated aircraft noise. Springfield, VA: Armstrong Laboratory AL-TR-1991-0123, National Technical Info Service; 1992. p. 23–35.
- [20] McGlothlin JA, Lester GD, Hansen PJ, Thomas M, Pablo L, Hawkins DL, et al. Alteration in uterine contractility in mares with experimentally induced placentitis. *Reproduction* 2004;127:57–66.
- [21] Kelleman AA, Luznar SL, Lester GD, Paccamonti DL, LeBlanc MM. Evaluation of transrectal ultrasonographic combined thickness of the uterus and placenta (CTUP) in a model of induced ascending placentitis in late gestation in the pony mare. *Theriogenology* 2002;58:845–8.
- [22] Calderwood Mays MB, LeBlanc MM, Paccamonti D. Route of fetal infection in a model of ascending placentitis. *Theriogenology* 2002;58:791–2.
- [23] LeBlanc MM, Sheerin P, Meisler SD, Cudd TA. Progesterone concentrations in serum and milk of mares during the last two weeks of gestation and in normal newborn foals. In: *Proceedings of a Havemeyer foundation workshop on disturbances in equine foetal maturation: comparative aspects*; 1992.
- [24] SAS Institute Inc., Cary, NC, USA.
- [25] Lang TA, Secic MS. How to report statistics in medicine. American College of Physicians; 1997. p. 147–169.
- [26] Santschi EM, Slone DE, Gronwall R, Juzwiak JS, Moll HD. Types of colic and frequency of postcolic abortion in pregnant mares: 105 cases. *J Am Vet Med Assoc* 1991;199:374–7.
- [27] Silver M, Comline RS. Transfer of gases and metabolites in the equine placenta: a comparison with other species. *J Reprod Fertil* 1975;23(Suppl):589–94.
- [28] Barnes M, Fite C, Tibary A. Trans-rectal ultrasonographic evaluation of the placenta in Arabian and pony mares in mid-to-late gestation. *Theriogenology* 2005;64:787.